

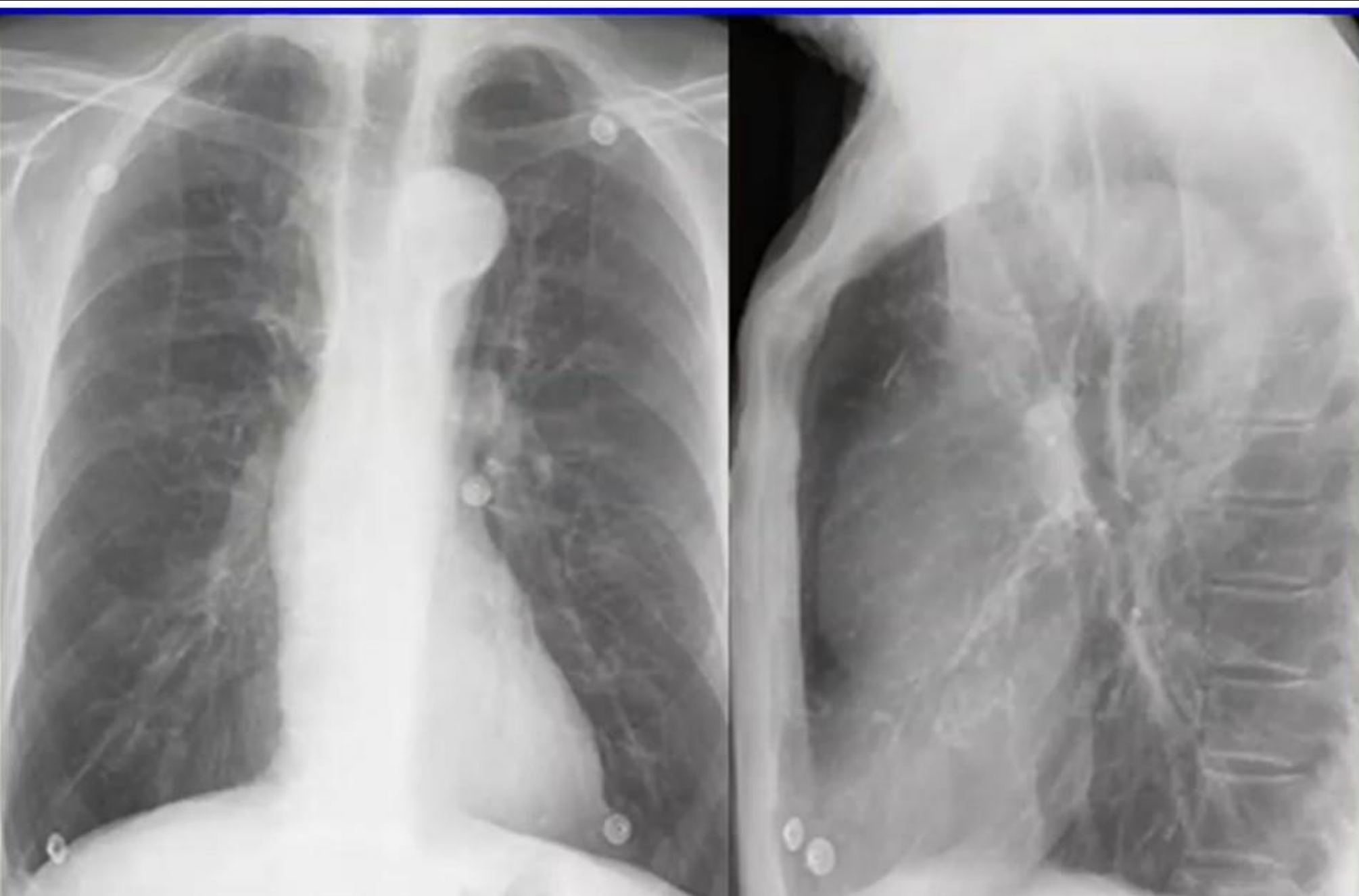
# Image of fortnight

Dr. A. Titus

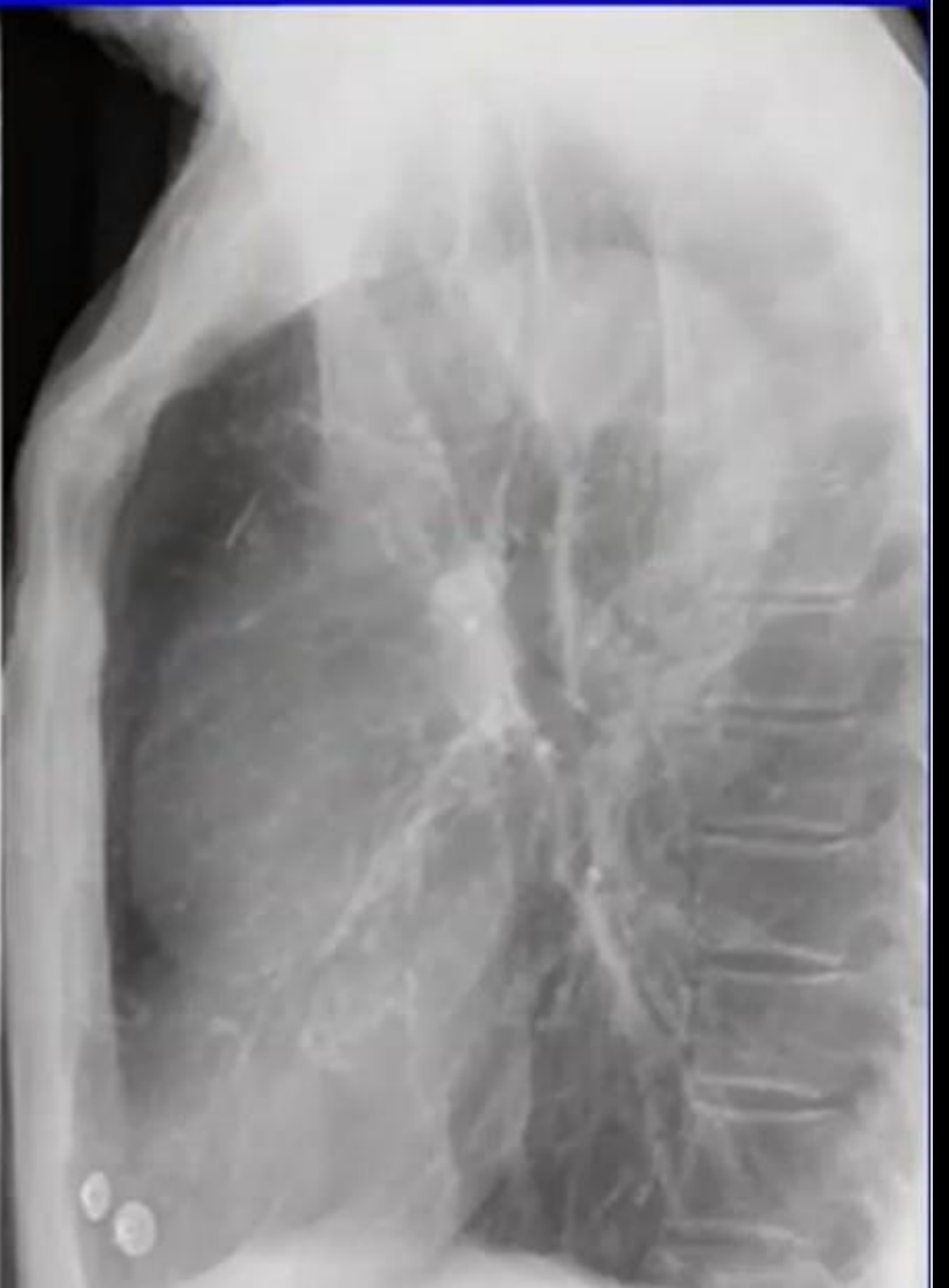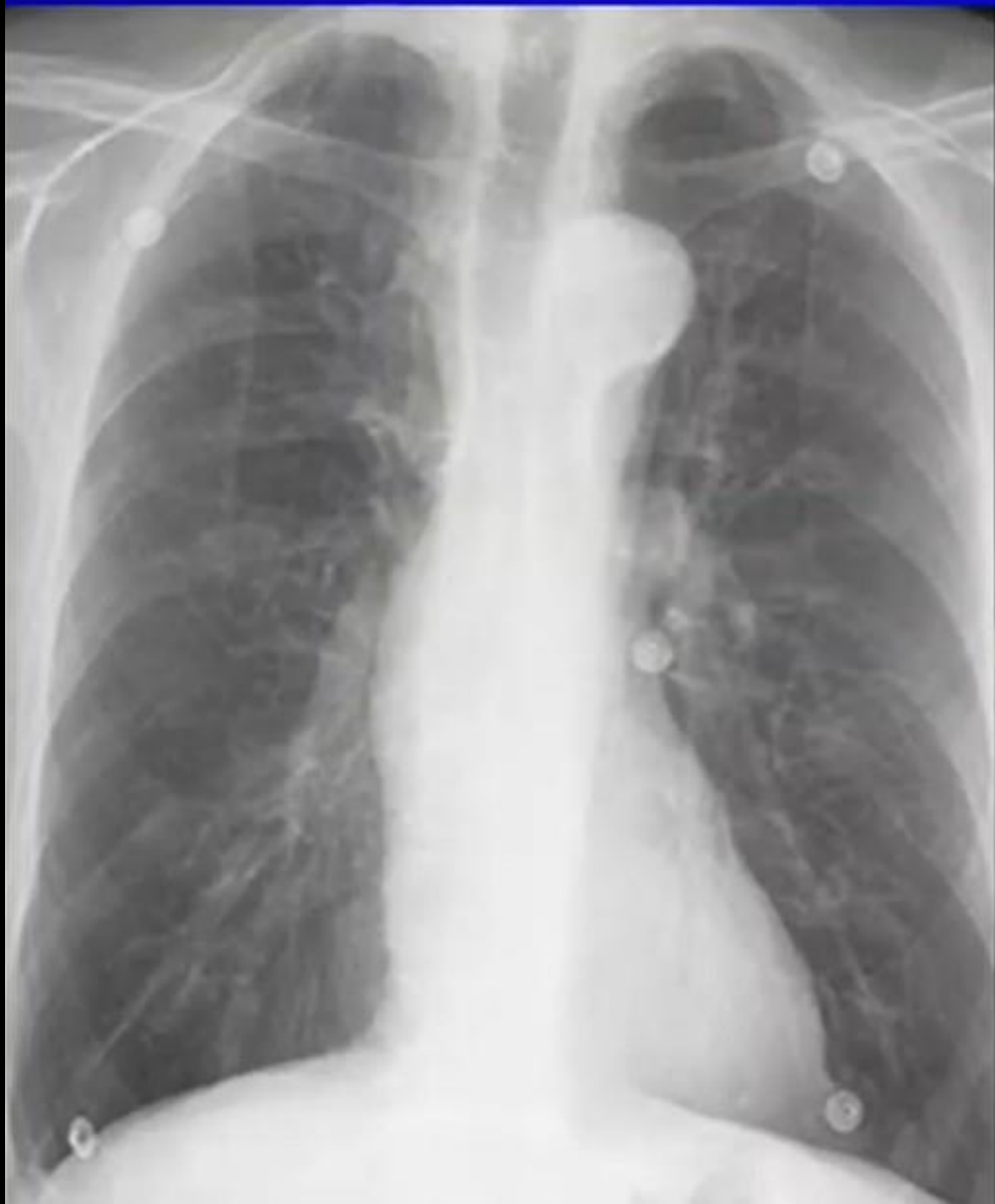Moderator: Dr. Ankamma rao sir,  
HOD, Dept of radiology

# Case details

- A 60 year old male presented with complaints of palpitations
- Chest Xray AP and lateral radiographs were advised.



What is the diagnosis?

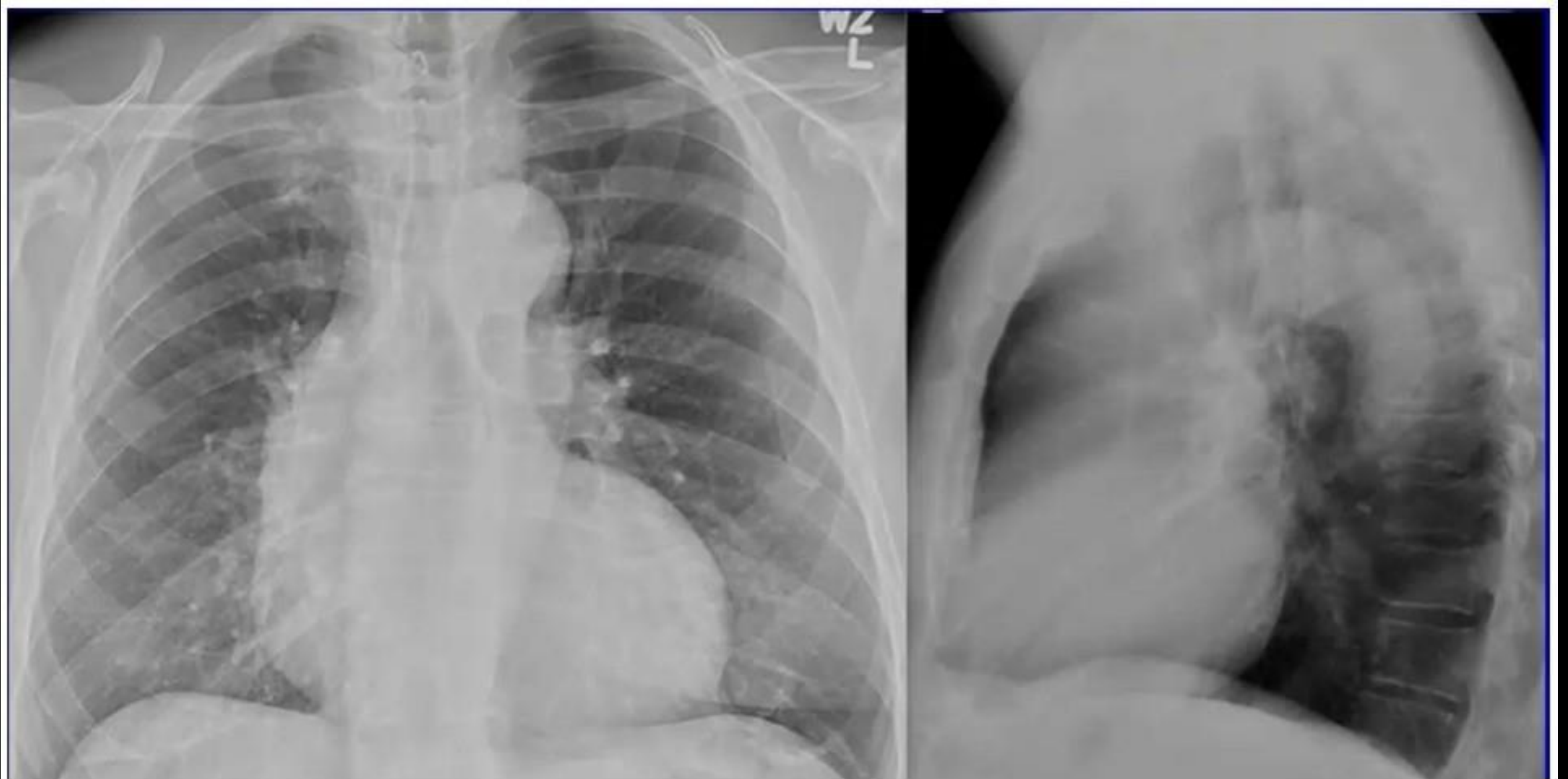


# AORTIC STENOSIS

## Typical CXR Findings:

- In early disease, the chest radiograph can be entirely normal or it may show dilatation of the ascending aorta with normal heart size.
- **Post-stenotic dilation** of the ascending aorta
- Pulmonary vasculature usually **normal** until late disease

# Differentials and distinguishing imaging features



- Differentiation with hypertension/ regurgitation can usually be made, as in later cases the entire aorta is enlarged and tortuous.

THANK YOU