

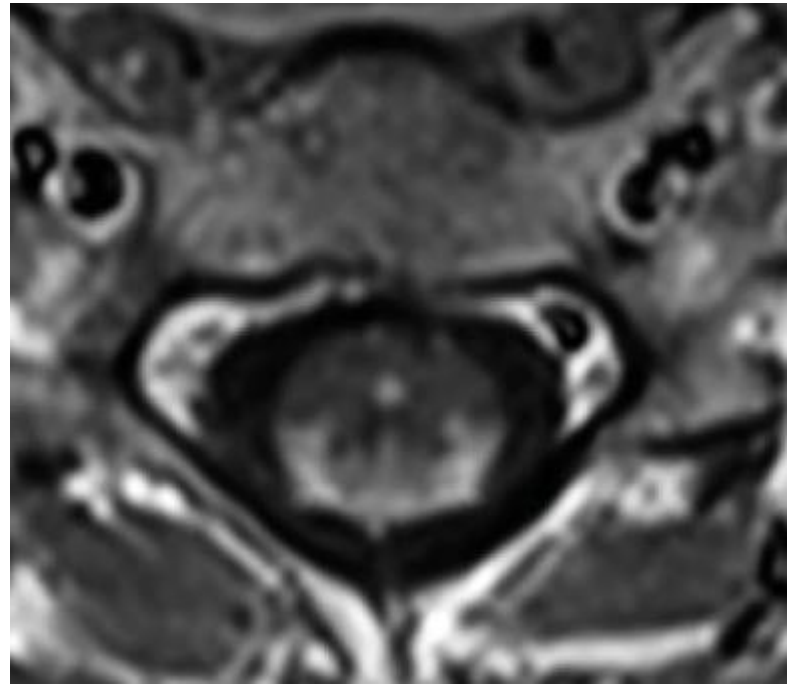
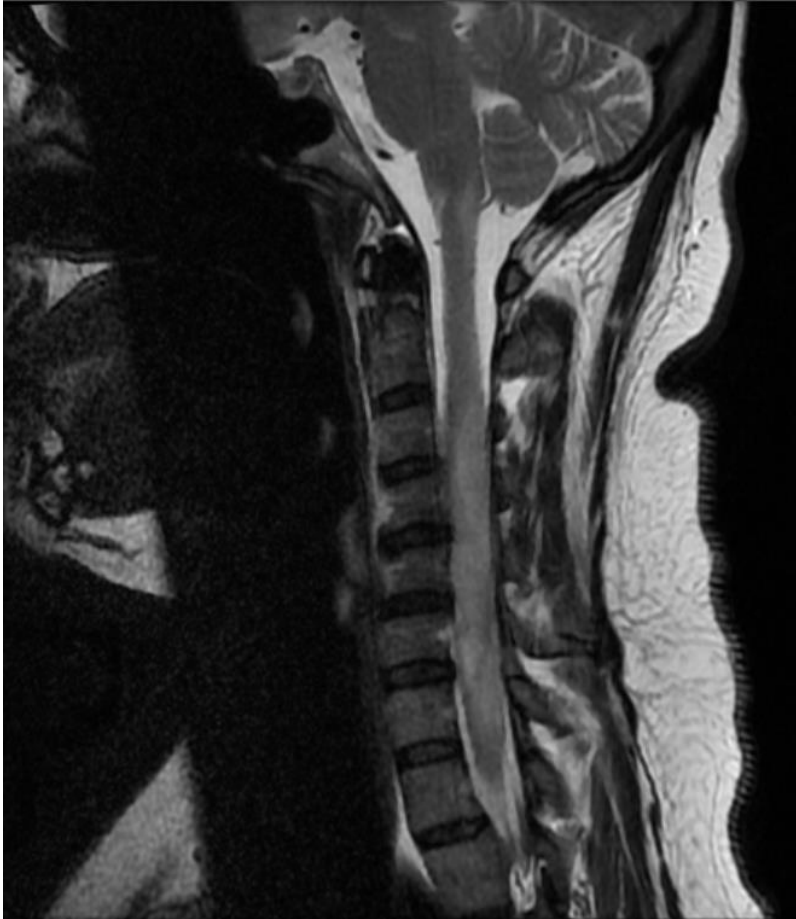

# IMAGE OF THE FORTNIGHT

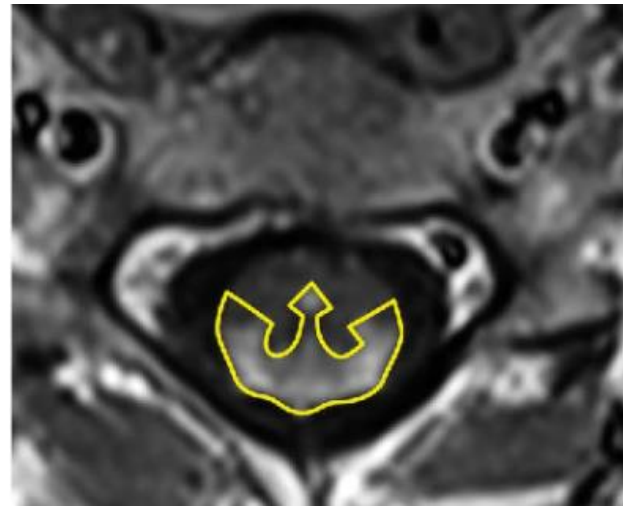
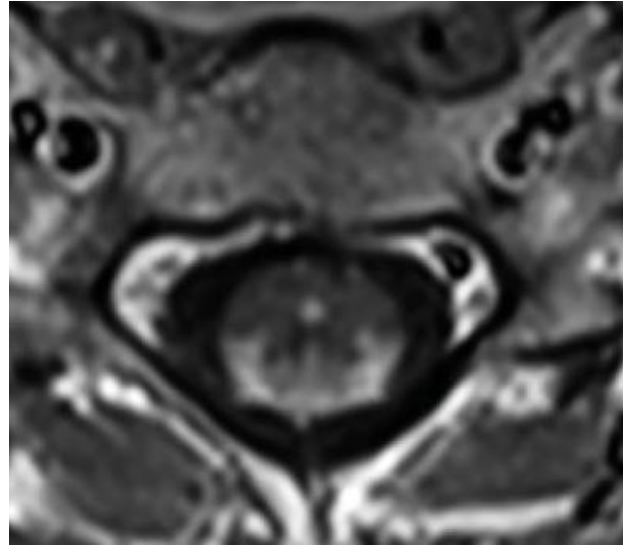
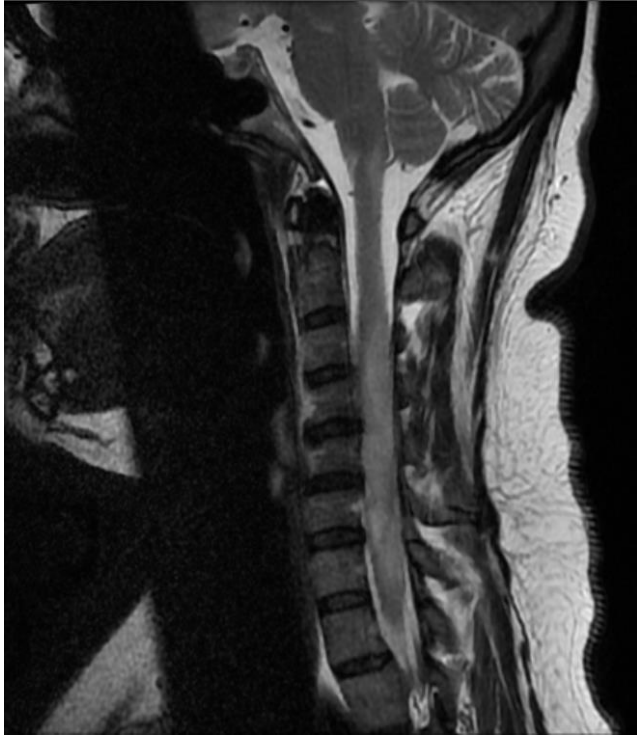NAME-DR.LAHARI POLA( 3rd year PG)

MODERATOR-DR.RASI PRIYA MA'AM,MD, RADIOLOGIST

Patient came with c/o bilateral lower limb weakness and paresthesias.



Name the sign. What is the diagnosis?



- **Trident sign** is formed by the axial appearance of a **longitudinally extensive transverse myelitis** due to spinal cord **neurosarcoidosis**, whereby on a T1-weighted post-contrast (gadolinium) MRI sequence, there is **central canal enhancement in addition to crescent-shaped posterior (dorsal) subpial enhancement**. This gives the appearance of a trident, a three-pronged spear.



THANK YOU